

# AOA Appliances, etc.


**AOA ALLESEE ORTHODONTIC APPLIANCES  
IN PARTNERSHIP WITH YOUR PRACTICE  
VOLUME 2, NUMBER 1, 1998**

## Thinking Appliances...

Thanks for making our inaugural *AOA Appliances, etc.* newsletter an instant success – the feedback we have received from our first issue has been overwhelming. Our goal is to continue to share with the profession new appliance designs, clinical applications, practice pearls and other related laboratory information. Your participation is greatly appreciated.

With our second issue, we are pleased to introduce Dr. Robert Workinger of Marshfield, Wisconsin, writing on cleft palate treatment utilizing Bonded Rapid Palatal Expansion Appliances. We are also delighted to introduce Dr. Larry Gaston, Hazelwood, Missouri, with his article on Modified Spring Retainers for post-treatment retention. In addition, we have included an article on Pre-treatment Diagnostic Set-ups and their value as a visual aid when consulting with your parents and patients. Finally, we have an update on the MARA Appliance and the overwhelming interest in this new appliance design, as well as an article from Dr. Jim Hilgers, Mission Viejo, California, on his new PhD Appliance.

These articles continue to demonstrate our commitment to share with the profession innovations and appliance news. Please remember to simply pick up the telephone and contact me, personally, to share any ideas you employ in your practice. I always look forward to hearing from you.



David Allesee  
General Manager,  
AOA Laboratory



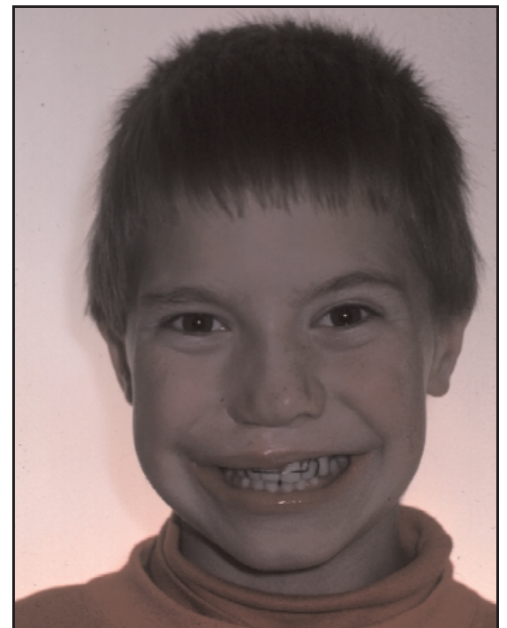by Dr. Robert Workinger  
Marshfield, Wisconsin

## Cleft Palate – A Case Report

This patient is a 9 year-old Caucasian male referred to me by an oral and maxillo-facial surgeon. The parents and patient presented with a chief concern of, "He was born with the cleft lip and palate and his teeth are not straight" (Figures 1 and 3).

The patient's past medical history was essentially normal except for a complete unilateral right cleft lip and palate. Tonsils and adenoid had not been removed. The clefts of the lip, soft and hard palates, had been previously closed. Speech correction had been recommended.

Cephalometric evaluation revealed a nine year old adolescent with a skeletal age of 7.8 years; growth to maturity 75% complete. He had an Angle Class II dental relationship and a mesocephalic Class II skeletal pattern due to both mandible and palate. There was a tendency toward a skeletal open bite due to both maxilla and mandible; the palatal plane was superiorly tipped 4.7 degrees relative to the Frankfort Horizontal Plane. The patient had a skeletal lingual crossbite due to both maxilla and mandible.



The panoramic radiograph showed normal development of all permanent premolars, and first and second molars; third molars were not evident. The maxillary right

*continued on following page*

# WORKINGER

continued from preceding page

cuspid, and the maxillary left and right permanent lateral incisors were congenitally absent. Two supernumerary teeth were present in the cleft site, as well as a residual maxillary left permanent lateral incisor which was nothing more than a mass of enamel embedded in the alveolus.

Since the root of the maxillary left cuspid was 50% developed, the surgeon felt that timing was appropriate for the palatal expansion to prepare the patient for surgery. The proposed surgical plan was mucosal pedicle graft over the alveolar defect. An autologous bone graft from the hip would be used to close the oronasal fistula, create a new nasal floor, and provide alveolar bone for eruption of the permanent cuspid.

Both the greater and lesser alveolar segments of the maxilla showed almost equal amounts of lingual collapse. Therefore, orthodontic treatment was initiated using a Bonded Acrylic Palatal Expansion Appliance with occlusal coverage of the posterior dentition. The transverse palatal screw was activated by a parent once a day (1/4 revolution per activation) until significant over expansion was achieved (Figure 2).

Following stabilization of the palatal screw, brackets were bonded to the maxillary central incisors. Rectangular tubes previously incorporated

into the buccal surfaces of the Bonded RPE appliance provided anchorage for a series of upper archwires (Figure 4). In due time, plastic pontics with attached brackets were tied to the archwire to provide esthetic replacement of the missing cuspid and lateral incisors.

It is important to note that the fixed expansion appliance was left in place for nine months following surgery – much longer than would be necessary in a non-cleft patient. This was necessary both to obtain maximum post-surgical healing and to facilitate regeneration of alveolar bone in the cleft site.

Fixed stabilization, such as a trans-palatal arch or a quad-helix, is usually recommended in this type of case. However, the patient and his parents proved extremely cooperative. This, and the need to optimize anterior esthetics, led to the choice of a Hawley type retainer with cuspid and lateral incisor points for intermediate stabilization (Figure 5).

The patient will now be followed on a regular recall basis until such time as definitive orthodontic treatment is indicated, with or without additional orthognathic surgery. Fixed prosthetic services will be the final stage of the overall treatment plan.



Figure 1



Figure 2

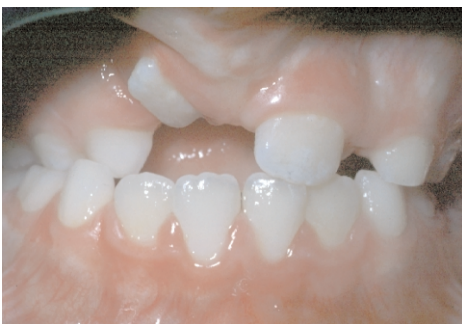

Figure 3

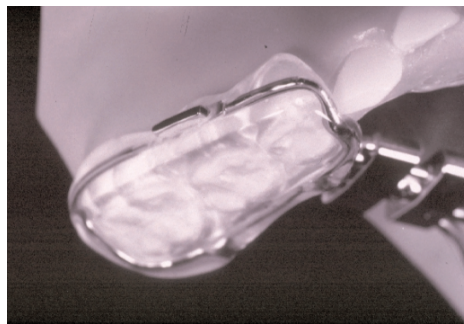


Figure 4

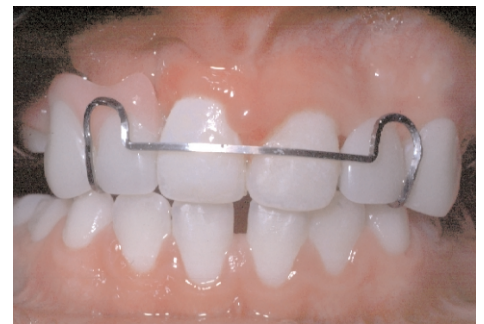


Figure 5

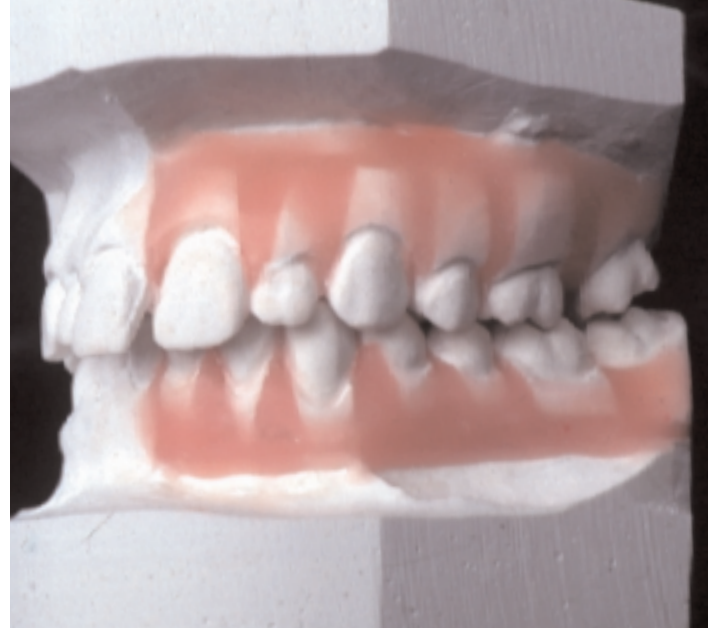# PRE-TREATMENT DIAGNOSTIC SET-UPS

The diagnostic set-up has been used by orthodontists for many years to aid in treatment objectives as well as a method of presenting treatment options and potential results to patients. The most common request or issue is whether to extract permanent teeth or treat non-extraction. Often times adults present with crowding of the anterior teeth as their chief complaint. The orthodontist might have several options to explore, including first bicuspid extractions, lower incisor extraction or interproximal reduction (stripping) to name a few. On occasion, combinations of the above scenarios are applied. Another interesting application of the diagnostic set-up is the joint or mixed dental team treatment approach with the use of traditional crown and bridge restoration, and now implants, in conjunction with orthodontics.

The requirements for having a diagnostic set fabricated by AOA are: 1) A quality model in either stone or plaster. The bases should be trimmed in centric occlusion and in scale to present an attractive set-up to the patient and referring or consulting dentist. If the models are to be preserved, please indicate on the Rx form that a duplicate model is to be used. This is our normal procedure. AOA will duplicate your casts for the purpose of constructing the set-up. 2) Indicate which teeth are to be reset. If, for instance, the upper and lower molars are in good occlusion and the treatment plan is to unravel crowded anterior teeth, the molars can remain unreset. Often, by leaving "landmark" teeth in this manner, a better or more practical result can be visual-

ized. If crown and bridge or implants are to be used in the treatment, just indicate the location and representative plaster pontics will be added to the set-up. If there is to be a surgical element to the treatment, for instance, a mandibular advancement, a wax shim will be added to the heel of the lower set-up model giving some perspective of the advancement.

The principle goal is to map out a successful treatment plan. However, the selling of the goal with the addition of a diagnostic set-up to the sophisticated patient should not be overlooked.




## Modified Spring Retainer Post-Treatment Retention

by Dr. Larry Gaston  
Hazelwood, Missouri

Our patients, both adolescent and adult, are subject to the same human behavior and sometimes fail to wear their retainers with enough consistency to maintain correct alignment.

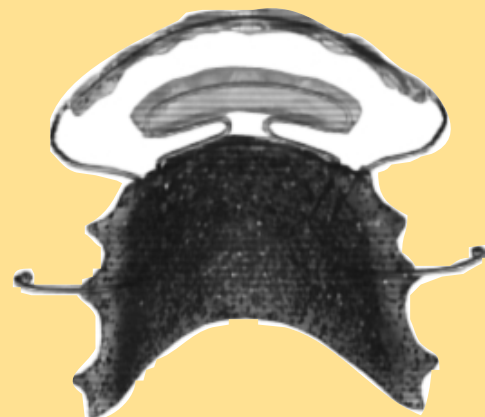
We have used modified Hawley/spring retainers for twenty years. In my hands, the traditional Hawley retainer was too rigid to effectively or comfortably restore alignment or correct all but the most minor rotational relapse of anterior teeth.

The spring retainer worn full time for a few days or weeks will correct fairly severe rotational relapse or misalignment. Following the loss of a retainer, I have



occasionally observed a severe relapse of the teeth which necessitated the use of two appliances: first, partial resetting of the teeth and a new appliance followed by full resetting of the teeth and a second retainer to complete and hold the correction. Spring retainers have allowed us to avoid returning to fixed appliances to correct a relapse or to treat adult patients needing only minor tooth movement.

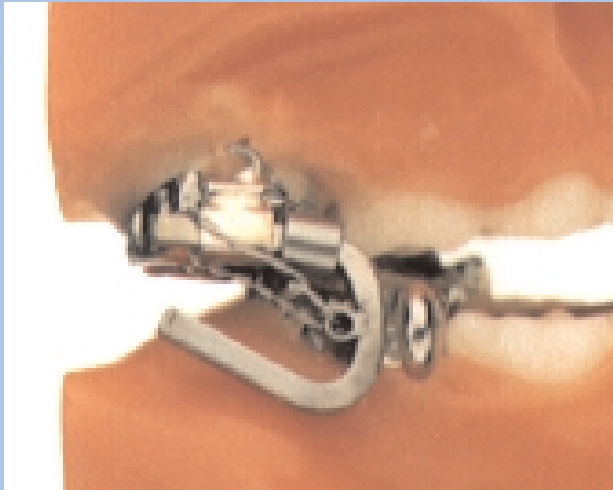We appreciate these retainers for their durability as well as their flexibility and the fact that they are removable offers the advantage of improved oral hygiene when compared to bonded retainers.



Mushroom Modified Spring Retainer

**IT'S A GOOD THING**

# MARA Update



The response to the MARA article has been terrific – this alternative functional appliance is quickly becoming known as a Fixed Twin Block® without acrylic. One of the most frequently asked questions concerns the archwire assembly. We have found that headgear and lip bumper tubes are generally not required and most of our input in this regard is to omit them from the standard design. Future MARA appliances will include a less bulky single tube designed in either .018 or .022 slot sizes which will be used as our “standard” if no reference is made on the individual prescription form.

Other comments and questions...

**“Can I adjust the upper elbow?”** Yes, we will return a special “torquing tool” with your first case to aid with adjustments to the elbows.

**“Can an expander be added to the upper appliance?”** Yes, but keep in mind that the upper elbows must be distal to the lower unit in order to prompt the jaw into a corrected Class I position. If more than 4-5mm of expansion is required, expansion should be accomplished prior to delivery of the MARA.


**“How can I advance or reactivate the MARA?”** Every appliance includes advancement bushings which easily slip onto the upper elbow.

*Remember, your first case will include the “Torquing tool,” additional elbows and advancement bushings.*

**AOA CUSTOMER SERVICE LINE**  
**800-262-5221**

# AOA on the Road

Our entire team will be attending the AAO Meeting in Dallas, May 14-20, 1998. If you are planning on attending the meeting, please stop by to review a variety of Fixed and Removable appliances that we will have on display. This will include our new MARA appliance, Lingual Indirect Bonding service and design variations of the Herbst.



Paula and Max will be traveling throughout the regions over the summer months attending programs by Dr. Hilgers, Dr. Mayes and Dr. Dischinger. Please feel free to contact Patti Dodge should you be interested in having them stop by your office – if they are in your area, they would welcome the opportunity to review your current appliance designs.



**Max Hall & Paula Allen** travel around the country representing AOA, attending numerous study clubs, society meetings and continuing education courses. Combined, they have over 40 years of experience in the laboratory business and are available to speak at your local meeting.

**MAY**  
14-20 AAO Meeting – Dallas

**JUNE**  
3 Dr. Hilgers – San Francisco  
5 Dr. Hilgers – St. Louis  
15-19 Midwest Regions

**JULY**  
6-10 Montreal  
13-18 Los Angeles  
31-Aug. 1 GORP – Ann Arbor, MI

**AUGUST**  
10-13 Chicagoland area  
24-27 Rochester/Buffalo

## Take 25% Off Your First Hilgers PhD Appliance

- Complete the information in the space provided.
- Enclose this coupon in the shipping box along with the case and send to AOA Laboratories, Attention: Patti Dodge.
- Shipping boxes and prescription forms can be obtained by calling Patti Dodge at AOA at 800-262-5221.

Name \_\_\_\_\_  
Address \_\_\_\_\_  
Phone \_\_\_\_\_

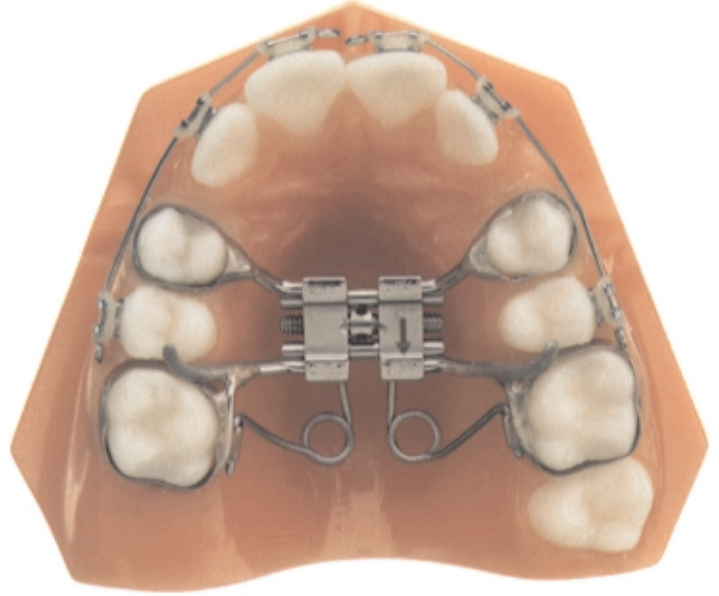# The Hilgers PhD

**T**he advent of TMA™ wire springs used in conjunction with acrylic button type appliances to distalize molars has been a wide spread clinical success. The evolution of this appliance as introduced by Dr. Jim Hilgers has included the addition of “locking wires” soldered to the molar bands (T-Rex appliance) so the appliance can act as an expander prior to molar distalization. A new approach utilizes a hygienic type RPE screw without any palatal acrylic. The TMA springs are seated into sheaths which have been laser welded to the palatal side of the screw body. Traditional spot welding may not be durable enough to withstand the forces created by the TMA springs.

The PhD appliance is securely anchored to the patient's teeth by first bicuspid bands when possible and bondable rests on the occlusal surfaces of the second bicuspids or second deciduous molars. Expansion is gained before the molars are distalized. Due to the unique properties of TMA the springs can be preactivated, inserted into the lingual sheaths on the molar bands and held until the “locking wires” are cut after transverse width has been gained.



To have AOA fabricate the PhD, forward an upper model in a good quality plaster or stone with molar bands seated. AOA will provide the lingual sheaths. Allow approximately 5-7 in-lab working days for fabrication.



**AOA CUSTOMER SERVICE LINE – 800-262-5221**

**WEBSITE – [www.ormco.com/aoaapps.html](http://www.ormco.com/aoaapps.html)**



P.O. Box 725  
Sturtevant, WI 53177