

AOA appliances, etc.

In This Issue:

- MARA to correct Class II Adult
- David Allesee 30 Years
- Versatile RWB System
- RWB Discount Coupon



We are proud to introduce our 11th edition of *AOAppliances, etc.* – it seems like yesterday that we were rolling out our first edition!! Obviously, the success of our newsletter is because of you, our loyal customer. We thank you for your support, constant e-mails and telephone calls offering suggestions and interesting articles to share with our profession.

In this article, we are proud to once again introduce Dr. James Eckhart – Jim is sharing an excellent case report involving the successful treatment of an adult male utilizing the MARA (Mandibular Anterior Repositioning Appliance) and traditional S.W. mechanics. Again, we see the enormous versatility of this very popular appliance.

I am personally humbled to reflect upon my 30 years of service in the orthodontic industry – so many memories, so many stories!! I would like to say a big “thank you” to the entire orthodontic family for making my 30 years very gratifying. I have taken a few moments to reminisce – thought you might enjoy a little of my history.



Dr. James Eckhart, DDS
Manhattan Beach, CA.

Using the MARA to Correct Class II's in Adults:

Most orthodontists acknowledge that Class II malocclusions can be stably corrected by holding the mandible forward for several months, and a wide variety of removable devices have been shown to be effective in this. However, the general evolution in orthodontics for the past fifteen years has been toward non-removable Class II correction devices because they are more reliable. There are many auxiliary springs and telescoping struts available to “permanently” attach to teeth or to braces to hold the mandible forward during this treatment time. Studies have shown that if the devices are worn long enough, the condyles are not abandoned in a postured-forward position, but are re-centered in the fossae.

Many orthodontists have even found adult Class II treatment has been effectively accomplished with non-removable posturing devices, not because the mandible grows, nor because the mandible is left with the condyles forward of the fossae, but because the teeth migrate within the dentoalveolar tissues sufficiently to achieve the Class II correction. This migration involves the upper teeth moving distally and the lowers moving mesially.

The **MARA** is different than other fixed (cemented) Class II correctors in that it does not require connection between the jaws, employing instead two vertical surfaces abutting each other. Patients appreciate this reduced bulk and increase in jaw movement freedom. The use of the **MARA** to treat adults has been described elsewhere, including what differences in response were noted between adults and children. This article will present one adult case treatment.

An Adult Class II MARA Treatment:

A 38-year-old male, WS, presented with a bilateral Class II deep bite, with a telescope cross bite on the right, and crowding and rotations in both jaws. His roots were quite long, so slow tooth movement was expected.



David Allesee
General Manager,
AOA Laboratory

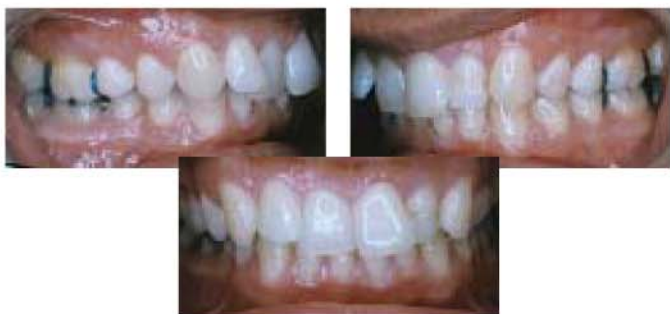

13931 Spring Street, Sturtevant, WI 53177
800-262-5221 Fax 262-886-6879
262-886-1050 (International)

6 Niblick Rd, Enfield, CT 06082
800-826-2224 Fax 860-741-7655
860-741-3745 (International)

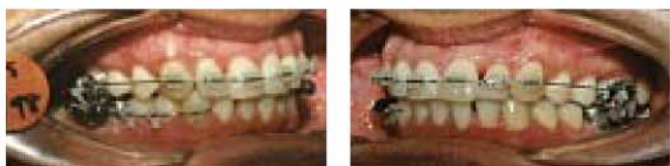

Continued on page 2

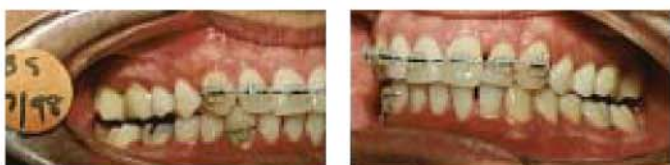

A lower lingual expanding arch was placed to widen the lower right quadrant. Upper edgewise brackets were placed to align the incisors.

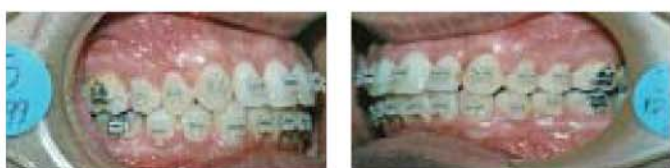After four months, a **MARA** was placed. The lower expanding arch was removed and replaced with a lingual arch to stabilize the **MARA**. The **MARA** was worn for eighteen months. Four months before the **MARA** was removed, brackets were placed in the lower right quadrant to further correct the telescope crossbite.



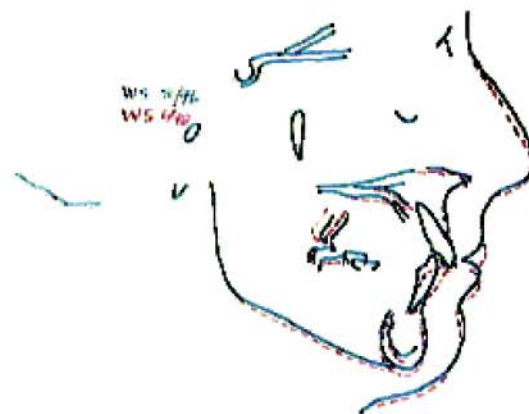
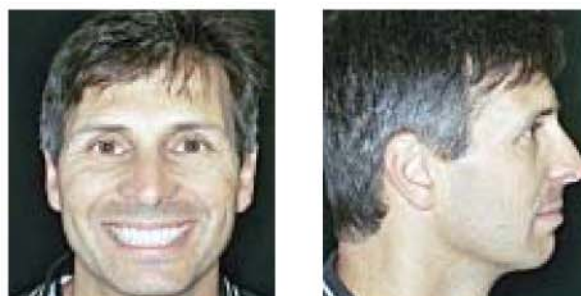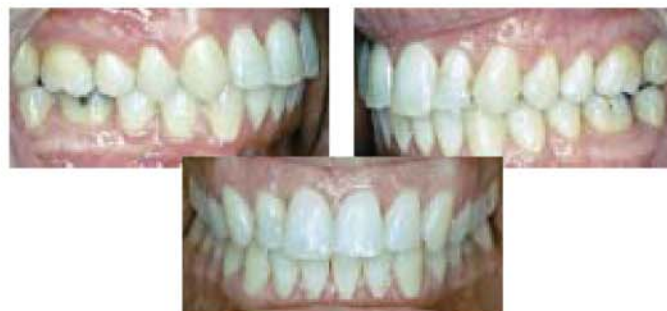When the **MARA** was removed, the remainder of full edgewise brackets were placed and the teeth were leveled to large rectangular wires, taking ten months.



Class II elastics were begun in the midpoint of this leveling and continued for eighteen months, during which bracket repositioning and detailing also occurred.



A fibrotomy was done to relax the stretched gums, braces were removed, and nighttime retainers were given with instructions to wear them every night forever.



Conclusion:

Stable Class II correction can be achieved in some adults without extraction and without mandibular advancement surgery, even in severe cases. This case could have been treated faster had full brackets been placed sooner so that leveling was occurring concurrently with the **MARA** wear. Additional efficiency would have involved the use of Damon brackets, for faster leveling.



Wow! Thirty years! It is hard for me to believe I've had the privilege of serving the Orthodontic profession since 1974. So many memories and so many people to thank.

My first thought is of my uncle, the man who believed in me when I was a youngster and offered the opportunity to begin my career in orthodontics following graduation from Ball State University. That fellow, Dick Allesee, is and will always be my Number One mentor.



Dick and Dave Allesee SAO Meeting Boca Raton, Florida

I joined PROfessional Positioners in 1974. That laboratory specialized in custom crafted Positioners and also offered an indirect banding service. Can you believe we were still pinching bands thirty years ago ??

PROfessional Positioners allowed me the opportunity to travel the country visiting orthodontic residency programs, numerous continuing education and study club programs and an

unlimited amount of component meetings and National AAO's. This exposure granted me the privilege of meeting many of the finest men and women practitioners in the country. Their impact on me was substantial and the professional relationships and personal friendships continue. I thank you all for maintaining these relationships for over 30 years.

My very first Orthodontic component meeting was the Southwestern Society in Corpus Christi, Texas, in 1974. Dr. O.B. Vaughn, the president that year, walked up to the exhibit



David Allesee Pro Lab 1974

table and asked me to explain the different Positioner materials that were available. Dick and I had displayed a variety of choices and I responded to Dr. Vaughn by saying "they come in either white, black or pink;" however, I had no clue how they were manufactured.

Subsequently, PRO developed transparent Positioner materials and worked with Dr. Raymond Thurow on the development of the Hinge Axis Tracing concept.



Dr. David Hamilton Study Group Meeting 1976

At about the same time, we began working with Dr. Eugene Williamson, who helped us develop the gnathological concepts of mounting Positioner Set-ups in an articulator – the Denar Phenomena began !! We also had the good fortune of knowing Mr. Woody Gordon who, through his collaboration with Dr. Ronald Roth, allowed us to process Positioners utilizing their gnathological principles.

I also remember when Dr. Harry Barrer brought to us the cuspid to cuspid Spring Retainer design – he utilized this appliance to treat relapsed lower incisors. PRO was instrumental in modifying the design, with assistance from Dr. John Johnson, by combining the Hawley Appliance with Dr. Barrer's design. The Modified Spring Retainer is now universally recognized as a proven appliance in treating relapsed cases.



Dr. Rolf Frankel with Drs. Dan Dunwoody, Eugene Williamson and David Allesee

I well remember being introduced to the Frankel Appliance in 1979. Orthopedic challenges in treatment philosophy were being expressed by Dr. Rolf Frankel, who convinced Dr.'s James McNamara, Mike Dierkes and Robert Scholz to visit him in what was then East Germany. The rest, as we say, is history !!

In the 80's, we began the development of the Herbst Appliance and introduced a variety of anchorage systems: acrylic, casted, banded, crowns and combinations of the above. Creative clinicians throughout the world worked with us on additional design variations.

As we moved into the 1990's, Hyrax Appliances were improved with molar only modifications (no longer four bands). A new relationship was established with

Dr. James Hilgers involving his Pendulum and Pendex distalization appliances. Dr. Joe Mayes offered modifications and a whole new Distalized Appliance design swept the market.

Continuing in the 1990's the Herbst Appliance grew rapidly. We also had the pleasure of working with Drs. James Eckhart and Doug Toll in providing their MARA Appliances, which offered an additional, excellent alternative to the many other types of Functional Appliances.

Going forward into the new millennium, relationships with Drs. Steve Hanks, James Mah, David Carter, Dwight Damon, Terry and Bill Dischinger and others will keep us "fully engaged" on refinements and the development of new appliances.

I am so proud to have been in a position to "listen" and "take advantage of opportunities." Thank you for making my past 30 years so enjoyable – I look forward to growing old with many of you for years to come !!

Dr. James McNamara,
Paula Allen and
David Allesee.
McNamara Course
1979



AAO Foundation
Golf Tournament
David Allesee,
Floyd Pickrell,
Dr. James Hilgers,
Mark Clineff and
Ernie Straub



In recognition of David Allesee's 30 year anniversary in the orthodontic industry, you are entitled to a:



\$30.00 discount off of your next Red, White & Blue Appliance




Please enclose this coupon with your models and corresponding prescription form. This discount is good for one case per office, including those offices with multiple locations.



This certificate is valid through December 31, 2004

The Versatile Red, White & Blue System

.....a great topic for your next staff huddle



AOA can provide the direct marketing materials for your waiting area, or your referring dentists' offices. These professionally designed resources will catch the eye of your patients as well as educating them about the possibilities of this unique treatment option. You are reinforced, as the dental professional, in this literature as the person to guide the patient to the best treatment technique.

Where does the Red, White & Blue system fit into your practice?

- Minor incisor alignment - Patient doesn't want to wear "braces".
- Positioning anterior teeth for future restorative treatment.
- Detailing anterior alignment when patients transition from brackets to retention.
- Refining post - ortho patients that may be concerned about slight relapse.

Let the patient touch and examine the appliances.

AOA has developed a Typodont Consultation Kit to allow the patient the opportunity to "check-out" the appliance and buy into the system. Cost to the practice is easily made up with the first patient, and the typodonts are made of AOA's exclusive non-breakable model urethane plastic. The binder keeps the set organized and ready to use.



Call your Customer Support Representative and ask to have our literature forwarded to your office. Pass it around at your next "huddle" and see if this great product has a place in your practice.


SEE REVERSE SIDE FOR RED, WHITE & BLUE
DISCOUNT COUPON

1974 **30** YEARS 2004
DAVID J. ALLESEE
AOA LABORATORY, INC.



AOA's famous Urethane Typodonts are available in binders categorized by related types. Or, you can customize your own binder. Specially priced and designed to help keep the models organized and impressive to the patient.

**Call for details:
1-800-262-5221**



Where to Find AOA This Year

- April 2 Drs. Terry & Bill Dischinger
Herbst/Damon Course
Boston, MA
- April 5 Illinois Society of Orthodontist
Oakbrook, IL
- May 1-5 AAO – Orlando, FL
- June 11-12 Drs. Terry and Bill Dischinger In-Office
Lake Oswego, OR
- August 6-7 Graduate Orthodontic Resident Program
Ann Arbor, MI
- August 20-21 Dr. Alan Bagden In – Office
Springfield, VA
- August 25-27 Charlene White Progressive Concepts
Myrtle Beach, SC

You can also find us at all of the AAO Fall Component Meetings. Make sure to stop by and see what's new with the Herbst, MARA and Red, White & Blue cosmetic retainer system.